



The Calgary protocol for bracing of pectus carinatum: a preliminary report

Dragan Kravarusic^a, Bryan J. Dicken^c, Richard Dewar^a, James Harder^a,
Philippe Poncet^a, Mark Schneider^b, David L. Sigalet^{a,*}

^aDepartment of Pediatric Surgery, Alberta Children's Hospital, Alberta, Canada T2T 5C7

^bBraceworks-Custom Orthotics Inc, Calgary, Alberta, Canada T3E 2J6

^cDepartment of General Surgery, University of Alberta, Edmonton, Alberta, Canada T6G 2E1

Index words:

Pectus carinatum;
External bracing;
Adjustable device

Abstract

Background: The optimal treatment of pectus carinatum (PC) deformities is unclear. We propose a nonoperative approach using a lightweight, patient-controlled dynamic chest-bracing device.

Material and Methods: With ethical approval, 24 patients with PC were treated at the Alberta Children's Hospital between January 1998 and April 2005. There were 6 (25%) females and 18 (75%) males, with a mean age of 12.9 years at the onset of treatment. Treatment involved fitting of a lightweight, patient-controlled chest brace, worn for 23 hours per day (correction phase [CP]) until the convex deformity was corrected. Following correction of the deformity, bracing was reduced to 8 hours per day (maintenance phase) until axial skeletal maturation ceased. Monitoring was done by measurement of the external pectus carinatum protrusion as well as subjective patient and surgeon appraisal of appearance and exercise tolerance.

Results: Nineteen (79.2%) patients have completed initial treatment (mean CP time, 4.3 ± 2.1 months). There were 3 patients (12.5%) who were noncompliant, and 2 (8.3%) are still in the initial CP phase of therapy. Fourteen (58.3%) patients are presently in maintenance phase, nocturnally braced, and 2 (8.3%) have completed therapy. In patients completing initial treatment, the protrusion pectus carinatum protrusion (pre 22 ± 6 vs post 6.0 ± 6.2) and subjective appearance (change $+1.8 \pm 0.4$) showed a significant improvement ($P < .001$ for both) with no change in exercise tolerance.

Conclusion: Compressive bracing results in a significant subjective and objective improvement in PC appearance in skeletally immature patients. However, patient compliance and diligent follow up appear to be paramount for the success of this method of treatment. Further studies are required to show the durability of this method of treatment.

© 2006 Elsevier Inc. All rights reserved.

Pectus carinatum (PC) is a common pediatric condition, characterized by an idiopathic overgrowth of the costal cartilages resulting in protrusion of the sternum. The severity of this abnormality generally worsens during the growth spurt of adolescence. The overall prevalence of PC is 0.6%; it is more common in boys [1,2]. The cause of PC is unknown;

Presented at the 37th Annual Meeting of the Canadian Association of Paediatric Surgeons, Quebec, Canada, September 22-25, 2005.

* Corresponding author. Tel.: +1 403 943 2271; fax: +1 403 943 7634.

E-mail address: dkravarusic@yahoo.com (D.L. Sigalet).

however, it may be genetically linked considering its recurrence in families. PC may occur as a solitary abnormality or in association with other genetic disorders or syndromes (eg, trisomy 18, Marfan syndrome, homocystinuria, Morquio syndrome, and Ehlers-Danlos syndrome). Of the musculoskeletal abnormalities, scoliosis is most frequently associated with PC [3]. Associated symptoms with PC are quite variable. Some children will experience tenderness, bone pain, or increased respiratory effort during exercise [4]. Unlike pectus excavatum, PC is rarely associated with significant cardiopulmonary derangement except in severe cases [5,6].

The classical management of pectus deformities, both carinatum and excavatum, has been primarily surgical [7-10]. Surgical intervention is generally a modification of the Ravitch technique that uses resection of the deformed costal cartilages along with sternal osteotomy. However, the long-term results of surgical intervention have been mixed, with worsening cosmetic results and decreased chest wall compliance over time [11-13]. Recently, there has been a surge of interest in the repair of pectus excavatum using a less invasive procedure. The Nuss procedure uses an internal support bar and results in remodeling of the chest wall cartilage [14]. These techniques have demonstrated the plasticity of the chest wall and have led us to hypothesize that carinatum defects would also remodel in response to chronic pressure, leading to a cosmetically superior, nonoperative result. This results details our preliminary experience with this treatment.

1. Material and methods

Since 1998, a protocol of external bracing of PC was developed. A key element of this was redesign of the external bracing device. We moved away from the previously used scoliosis jacket to a lightweight aluminum bar with padded back support and a patient-controlled tensioning device (Fig. 1). Pectus carinatum protrusion (PCP) was measured as distance from maximal protrusion point and expected contour of chest wall. All patients with significant defects (protrusion of >2 cm) were offered bracing. After recording

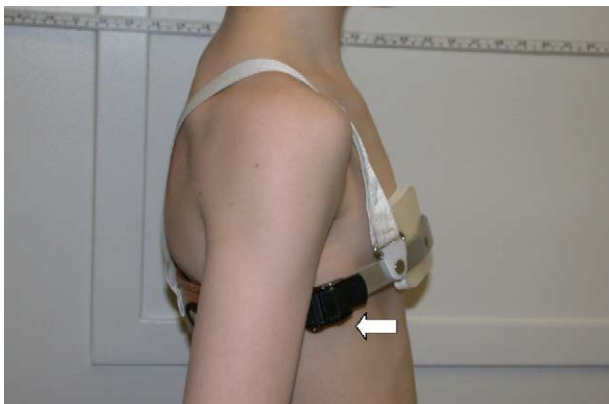

Fig. 1 Braceworks, Calgary—patient with fitted external brace, arrow showing controlled adjustable device.

Table 1 Patient characteristics (N = 24)

Gender	
Male	18 (75.0)
Female	6 (25.0)
Family history of PC	
No	22 (91.7)
Yes	2 (8.3)
Tanner stage at diagnosis	
I	1 (4.2)
II	4 (16.7)
III	5 (20.8)
IV	14 (58.3)
Pulmonary symptoms at presentation	
No	14 (58.3)
Yes	9 (37.5)
Missing	1 (4.2)

Data presented as number (percentage).

of baseline data, patients were fitted with the adjustable tension brace. The patients were instructed to wear the brace for 23 hours (correction phase [CP]) until the external defect was flattened; thereafter, bracing was reduced to night hours (maintenance phase) until axial skeletal growth had ceased. This protocol evolved from our initial experience with shorter periods of overnight bracing. Patients would report that the protrusion would correct overnight and recur over the day when the brace was not done. Improvement in the deformity was rated by measurement of the external protrusion (PCP), subjective patient opinion, surgeon appraisal of appearance, and patient-reported exercise tolerance.

Our study entails a retrospective review of all patients who were treated by this external bracing in the pediatric congenital chest wall database at the Alberta Children's Hospital between January 1998 and April 2005. The surgeon's office data and the database of the orthotic maker were reviewed for patient names, and all families were then contacted for telephone consent to have their data extracted and included in this study. Our study was approved by the Conjoint Ethics Board of the Calgary Health Region. We obtained anthropometric, demographic (height, weight, and Tanner stage), and outcome data.

2. Results

Twenty-four patients with PC were identified from the pediatric congenital chest wall database at the Alberta

Table 2 Continuous variable characteristics of a cohort of patients treated with bracing for PC

	Baseline	Correction	Maintenance
Age (y)	12.9 ± 3.1	13.2 ± 2.1	15.7 ± 2.3
PCP (mm)	22.0 ± 6.0	6.0 ± 6.2*	4.3 ± 1.9*
Satisfaction (1-5)	2.3 ± 2.1	4.7 ± 0.9*	4.7 ± 0.8*

Data presented as mean ± SD.

* $P < .001$ vs baseline.




Fig. 2 Adjustable brace close up.

Children's Hospital between January 1998 and April 2005. There were 6 (25%) females and 18 (75%) males with a mean age of 12.9 years at the time of treatment (range, 5-16 years). Fourteen patients (58.3%) reported no symptoms before initiating therapy, whereas 9 patients (37.5%) cited subjective pulmonary symptoms as a determinant for therapy. Patient characteristics are presented in Table 1.

Nineteen (79.2%) of the patients enrolled have completed the initial orthotic treatment (mean CP time, 4.3 ± 2.1 months). Three patients (12.5%) were noncompliant in CP, while 2 (8.3%) are in the initial (CP) phase of treatment. Fourteen patients (58.3%) are presently in maintenance phase, nocturnally braced, and 2 patients (8.3%) have completed therapy. There was a significant improvement in the PCP pre- versus post-CP (22.0 ± 6.0 vs 6.0 ± 6.2 , respectively; $P < .001$). Although there was no significant change in reported exercise tolerance, patients reported a significant improvement in subjective appearance ($P < .001$; Table 2).

Overall, the orthotic treatment was well tolerated. Eleven patients (45.8%) had no discomfort, whereas 6 patients (25.0%) reported mild erythema at the bracing site, and 3 patients (12.5%) complained of pain. There were no instances of skin breakdown.

3. Discussion

In the current study, our data support that PC may be successfully treated by compressive, nonoperative techniques. A nonoperative approach using a dynamic chest compressor orthosis was first proposed by Haje and Raymundo in 1979 and further improved in 1988 [15]. Orthotics are designed to place the greatest external forces on the point of the most prominent sternal protrusion of the deformity to provide continued pressure to stimulate bone and cartilage remodeling. These early orthotics resembled a scoliosis jacket brace and were uncomfortable and difficult to adjust, making them very unpopular with patients. Modifications to the devices, such as fitting the lightweight aluminum buckle with an adjustable tension device allowing the patient to control pressure, significantly improved the compliance and the efficacy of this intervention (Fig. 2).

Observations from using compressive bracing in the management of PC strongly indicate a potential role for this

approach in the initial, if not definitive, management of selective forms of this deformity. Application of bracing in early teenage growth phase appears to be the optimal time for initiating this approach.

Patient compliance with regular brace wear and diligent follow up is paramount to the success of this method of treatment. Bracing by itself may not be effective unless the brace is worn for the correct daily number of hours according to each period of the treatment and applied along with an appropriate individual program of exercises [16,17].

Future studies by our laboratory propose to introduce the utilization of an external optical imaging system, commonly used for scoliosis, in our patients with PC [18]. Furthermore, every future patient from our prospective group will have contour mapping of the chest wall done and quantitative measures of chest wall deformity based on the standard x-ray or computed tomography findings as well as the new optical imaging technique. Interestingly, pilot data in 4 new patients allowed the generation of 3-dimensional torso surface models of our subjects. We anticipate using this enhanced technology and advanced analysis techniques to quantify the trunk topography of adolescents with PC deformities.

In summary, our results indicate that nonoperative bracing resulted in a similar short-term outcome compared with standard operative approaches. Nevertheless, long-term outcomes are still unknown; thus, multi-institutional studies comparing outcomes with the operative and nonoperative approaches will help to further define the full value of this major innovation in the treatment of PC.

Acknowledgments

Special thanks for the secretarial assistance of Gail Wright-Wilson and the assistance of the Laser Imaging Lab from the University of Calgary.

References

- [1] Welch KJ, Vos A. Surgical correction of pectus carinatum (pigeon breast). *J Pediatr Surg* 1973;5:659-67.
- [2] Shamberger RC, Welch KJ. Surgical correction of pectus carinatum. *J Pediatr Surg* 1987;1:48-53.
- [3] Saxena AK, Willital GH. Surgical repair of pectus carinatum. *Int Surg* 1999;4:326-30.
- [4] Shamberger RC, Welch KJ. Cardiopulmonary function in pectus excavatum. *Surg Gynecol Obstet* 1988;166:383-91.
- [5] Sigalet DL, Montgomery M, Harder J. Cardiopulmonary effects of closed repair of pectus excavatum. *J Pediatr Surg* 2003;38(3):380-5.
- [6] Cahill JL, Lees GM, Robertson HT. A summary of preoperative and postoperative cardiorespiratory performance in patients undergoing pectus excavatum and carinatum repair. *J Pediatr Surg* 1984;19(4):430-3.
- [7] Lam CR, Taber RE. Surgical treatment of pectus carinatum. *Arch Surg* 1971;103(2):191-4.
- [8] Singh SV. Surgical correction of pectus excavatum and carinatum. *Thorax* 1980;35(9):700-2.

- [9] Fonkalsrud EW, Dunn JC, Atkinson JB. Repair of pectus excavatum deformities: 30 years experience with 375 patients. *Ann Surg* 2000; 231:443-8.
- [10] Fonkalsrud EW, Beanes S. Surgical management of pectus carinatum: 30 years experience. *World J Surg* 2001;25:898-903.
- [11] Lacquet LK, Morshuis WJ, Folgering HT. Long-term results after correction of anterior chest wall deformities. *J Cardiovasc Surg (Torino)* 1998;39(5):683-8.
- [12] Haller Jr JA, Colombani PM, Humphries CT, et al. Chest wall constriction after too extensive and too early operations for pectus excavatum. *Ann Thorac Surg* 1996;61(6):1618-24 [discussion 1625].
- [13] Weber TR. Further experience with the operative management of asphyxiating thoracic dystrophy after pectus repair. *J Pediatr Surg* 2005;40(1):170-3 [discussion 173].
- [14] Goretsky MJ, Kelly Jr RE, Croitoru D, et al. Chest wall anomalies: pectus excavatum and pectus carinatum. *Adolesc Med Clin* 2004; 15(3):455-71.
- [15] Haje SA, Bowen JR. Preliminary results of orthotic treatment of pectus deformities in children and adolescents. *J Pediatr Orthop* 1992;12(6):795-800.
- [16] Egan JC, DuBois JJ, Morphy M, et al. Compressive orthotics in the treatment of asymmetric pectus carinatum: a preliminary report with an objective radiographic marker. *J Pediatr Surg* 2000;35(8):1183-6.
- [17] Mielke CH, Winter RB. Pectus carinatum successfully treated with bracing. A case report. *Int Orthop* 1993;17(6):350-2.
- [18] Poncet P, Delorme S, Ronsky JL, et al. Reconstruction of laser-scanned 3D torso topography and stereoradiographical spine and rib-cage geometry in scoliosis. *Comput Methods Biomech Biomed Engin* 2000;4(1):59-75.